

แบบส่งตรวจเซลล์วินิจฉัย

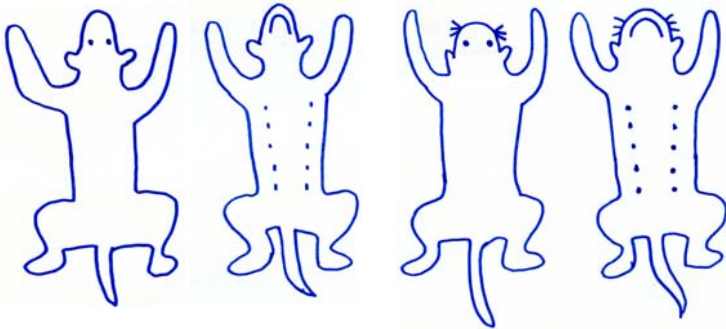
OPD NO.....

โรงพยาบาลสัตว์ มหาวิทยาลัยเกษตรศาสตร์ หนองโพ

วันที่.....เจ้าของ.....สัตว์แพทย์.....

ชื่อสัตว์..... dog cat อื่นๆ.....พันธุ์.....เพศ.....อายุ.....

Location of collection



Number of collection.....site

History & Sign

.....
.....
.....
.....
.....
.....

Tumor/Mass/Lymph node

color..... size.....cm
shape round oval ulcer other
consistency soft firm hard
content purulent seropurulent
 serosanguineous other
surface smooth rough
 multilobular ulcerated
margin sessile invasive pedunculated
number/percent involved
 solitary multifocal extensively multifocal
lymph node involvement
Method FNA impression smear
 swab scraping other.....

Effusion

- thoracocentesis
- abdomenocentesis
- transtracheal wash/lavage
- bronchoalveolar lavage
- synovial joint
- cerebrospinal fluid

Macroscopic appearance

color _____
transparency _____
turbidity _____
protein _____
total nucleated cell count _____
SP.GR. _____
other _____

Dermatology

Method swab
 other _____

Description

Comment

Cytologic Dx

Pathologist